



# Pulmonary infection caused by *Aspergillus glaucus* in patient with leucocytopenia

Chunhui Xu<sup>1</sup>, Shu Li<sup>2</sup>, Mi Zhou<sup>3</sup>, Yuetian Yu<sup>4</sup>

<sup>1</sup>Clinical Laboratory Center, Institute of Hematology and Blood Diseases Hospital, Chinese Academy of Medical Sciences and Peking Union Medical College, Tianjin 300020, China; <sup>2</sup>Department of Laboratory Medicine, Qinyang People's Hospital, Qinyang 454550, China; <sup>3</sup>Department of Pharmacy, Children's Hospital of Soochow University, Soochow 215000, China; <sup>4</sup>Department of Critical Care Medicine, Ren Ji Hospital, School of Medicine, Shanghai Jiao Tong University, Shanghai 200001, China

Correspondence to: Yuetian Yu. Department of Critical Care Medicine, Ren Ji Hospital, School of Medicine, Shanghai Jiao Tong University, 145, Middle Shan Dong Road, Shanghai 200001, China. Email: fishyyt@sina.com.

Received: 11 January 2019; Accepted: 19 March 2019; Published: 26 March 2019.

doi: 10.21037/jeccm.2019.03.02

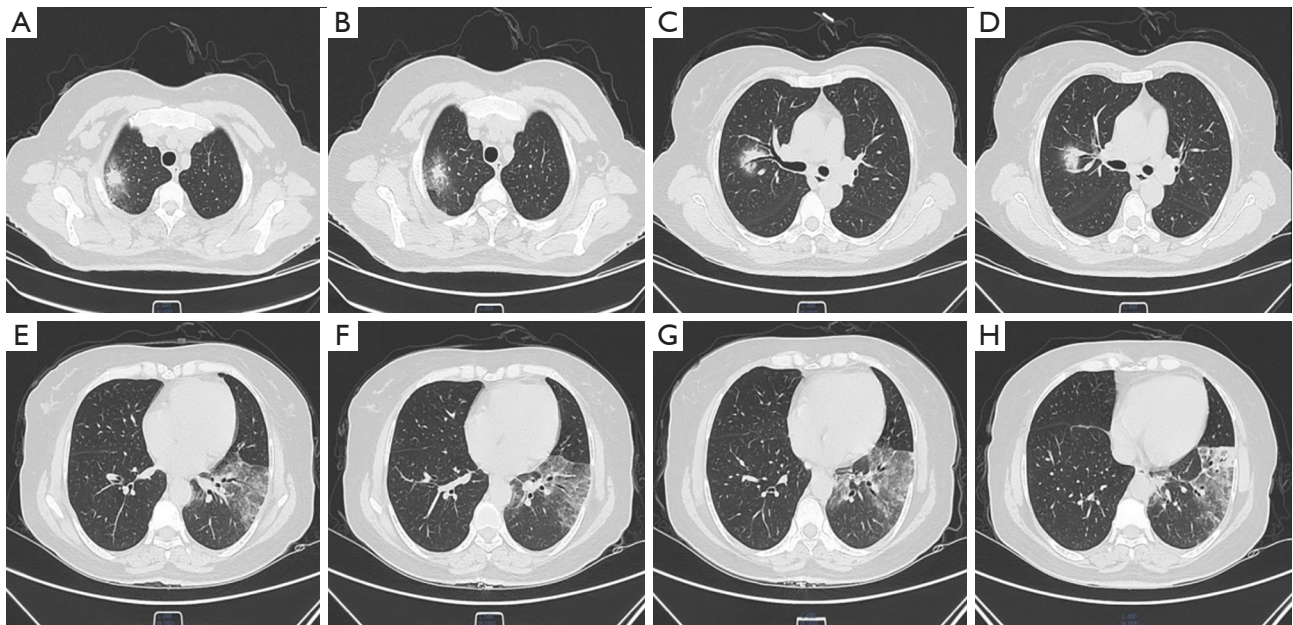
View this article at: <http://dx.doi.org/10.21037/jeccm.2019.03.02>

A 52-year-old female was admitted to our hospital with cough, fever and fatigue for a week. Her medical history included leukocytosis and myeloproliferative neoplasia for about 3 months. On physical examination, she appeared shallow breathing with fever up to 38.5 °C and moist rale could be clearly heard on the left lower lobe. Laboratory evaluation at the time of hospital admission revealed as follows: leukocyte count  $20.00 \times 10^9/L$ , absolute neutrophil count  $14.72 \times 10^9/L$ , platelet count  $400 \times 10^9/L$ , procalcitonin 1.22 ng/mL. The galactomannan antibody IgM of aspergillus was 132.19 Au/mL, which was far beyond the normal range. Chest computed tomography revealed hole sign in the right upper lobe and localized patchy clouding opacity with consolidation in the left lower lobe (Figure 1).

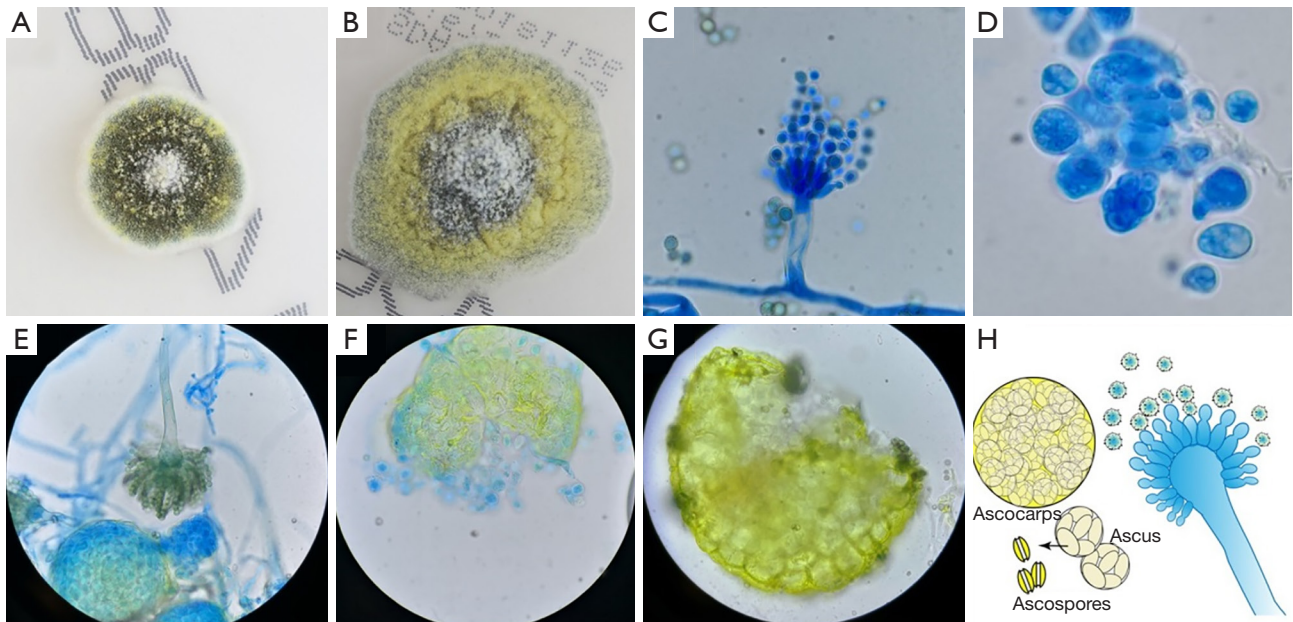
Grew floccose mold colonies after 9 days of incubation on Sabouraud dextrose agar could be observed from the sputum culture. These colonies displayed brownish green at the beginning, then presented yellow center. Microscopic appearance with lactophenol cotton blue staining showed predominant features consistent with *Aspergillus glaucus*.

These included vesiculate conidiophores and ascocarps. Phialides covered the entire surface of the vesicle. The round yellow ascocarps showed on the third days by the slide culture method. Matured ascocarps released ascus, in which there were eight ascospores (Figure 2). Therefore, invasive pulmonary aspergillosis (IPA) was probably diagnosed and voriconazole was initiated (intravenous medication, 200 mg q12 h).

Although *Aspergillus glaucus* is ubiquitous in warm moist environments, few cases of infections like IPA caused by the pathogen has been reported. Voriconazole might be one better choice to treat the diseases. However, the patient discharged voluntarily from the hospital without remission of symptoms after four days therapy and died one week later. Culture of *Aspergillus glaucus* from sputum sample is difficult since the organism requires at least about one week to grow on Sabouraud dextrose agar. Such a characteristic leads to the diagnosis of *Aspergillus glaucus* infection more complicated without a high index of clinical suspicion. An experienced microbiologist with better



**Figure 1** Chest computed tomography images. (A,B) Hole sign could be observed in the right upper lobe; (C,D) ground-glass opacities and air bronchogram in the right middle lobe; (E,F,G,H) localized patchy clouding opacity with consolidation in the left lower lobe.



**Figure 2** Morphology of *Aspergillus glaucus*. (A) Green floccose mold colony on Sabouraud dextrose agar after 6 days at 25 °C; (B) bright yellow colony on Sabouraud dextrose agar after 14 days at 25 °C; (C) microscopy of conidiophore (lactophenol cotton blue staining 1,000×); (D) microscopy of ascus (lactophenol cotton blue staining 1,000×); (E) microscopy of conidiophore and ascocarp (lactophenol cotton blue staining 400×); (F,G) Microscopy of ascocarps (lactophenol cotton blue staining 400×/1,000×); (H) *Aspergillus glaucus* diagram (drawn by Chunhui Xu).

identification methods are more important in the process of disease diagnosis and treatment.

### Acknowledgements

*Funding:* This work was supported by the Scientific Research Project of Shanghai Municipal Health Bureau (No. 201840006).

doi: 10.21037/jeccm.2019.03.02

**Cite this article as:** Xu C, Li S, Zhou M, Yu Y. Pulmonary infection caused by *Aspergillus glaucus* in patient with leucocythemia. J Emerg Crit Care Med 2019;3:18.

### Footnote

*Conflicts of Interest:* The authors have no conflicts of interest to declare.

*Informed Consent:* Informed consent was obtained for the use of information and images. The patient's identity has been kept confidential.